

# Chronic Knee and Ankle Pain Treatment through Selective Microsurgical Approaches: A Minimally Invasive Option in the Treatment Algorithm for Refractory Lower Limb Pain

Giorgio Pietramaggiori, MD, PhD<sup>1,2</sup> Gianluca Sapino, MD<sup>3</sup> Giorgio De Santis, MD<sup>3</sup>  
Franco Bassetto, MD<sup>2</sup> Saja Scherer, MD<sup>1,2</sup>

<sup>1</sup>Department of Plastic, Reconstructive and Aesthetic Surgery, Global Plastic Surgery, Lausanne, Switzerland

<sup>2</sup>Department of Plastic and Reconstructive Surgery, University Hospital of Padova, Padova, Italy

<sup>3</sup>Department of Plastic and Reconstructive Surgery, University Hospital of Modena, Modena, Italy

Address for correspondence Giorgio Pietramaggiori, MD, PhD, Department of Plastic, Reconstructive and Aesthetic Surgery, Private Docent, University of Lausanne, Global Plastic Surgery, Avenue Jomini 8, 1004 Lausanne, Switzerland (e-mail: dr.pietramaggiori@global.surgery).

J Reconstr Microsurg 2021;37:234–241.

## Abstract

**Background** Injury or compression of a sensory nerve is an under-reported source of disabling pain in the lower limb. It is known that peripheral nerve microsurgeons can reconstruct and rewire injured nerves to relieve chronic pain but this option remains not completely understood and ignored by most orthopaedic surgeons, neurologists, and pain therapists. In this paper, we describe our experience with knee and ankle peripheral nerve surgery to improve the condition of patients suffering from chronic, posttraumatic lower limb pain.

**Patients and Methods** Between 2015 and 2018, a retrospective investigation was performed including patients who underwent ankle and knee nerve surgery for posttraumatic chronic pain with at least 1 year of follow-up. Previous surgeries or type of trauma, pain location and characteristics, type of operation (reconstruction, decompression, or denervation), and number of nerves operated were listed. Selective neuropathy was confirmed by ultrasound-guided nerve blocks. Outcome was assessed combining the visual analogue scale (VAS) score at rest and during movement, functional indexes, drug use, and ability to work.

**Results** A total of 34 patients (14 knee and 20 ankle) were included in this study. A statistically significant difference ( $p < 0.05\%$ ) in postoperative pain at rest and during activity was seen in both groups of patients. Good to excellent outcomes were recorded in 92 and 80% of patients treated, respectively, at the knee and the ankle levels. No major complications occurred, while a secondary procedure due to neuroma recurrence was necessary in seven patients (three knees and four ankles).

**Conclusion** Peripheral nerve microsurgery is a useful and minimally invasive tool to be added in the algorithm of treatment of chronic knee and ankle pain. Physicians should be trained to suspect a neuropathic origin of pain in absence of musculoskeletal signs of pathology, especially following trauma or surgeries.

## Keywords

- ▶ chronic pain
- ▶ partial joint denervation
- ▶ knee pain
- ▶ ankle pain

received  
May 13, 2020  
accepted  
August 18, 2020  
published online  
October 7, 2020

Issue Theme World Society for  
Reconstructive Microsurgery 2019

© 2020, Thieme. All rights reserved.  
Thieme Medical Publishers, Inc.,  
333 Seventh Avenue, 18th Floor,  
New York, NY 10001, USA

DOI <https://doi.org/10.1055/s-0040-1717100>.  
ISSN 0743-684X.

Chronic, posttraumatic knee and ankle joint pain in the lower limb are highly disabling conditions, deeply affecting the ability to work, and quality of life of patients. The development of chronic pain often initiates a spiral leading to drug abuse and depression, aggravating the burden on overall health.<sup>1</sup> Depending on initial injury, traditional treatment options range from pain killer administration, physical therapy, and splinting to more invasive arthroscopy and sometimes joint replacement surgeries.<sup>2</sup>

The role of nerve surgery in relieve chronic, untreatable joint pain has been described first by Wilhelm for the wrist, using a complex operation which required several incisions to address all sensitive nerves (10) of the joint.<sup>3</sup> Results were encouraging, and many surgical modifications have been proposed since to minimize the surgical complexity while obtaining satisfactory denervation and pain control.<sup>4,5</sup> Dellon introduced the concept of partial joint denervation as a possible, simpler, and more effective approach to address chronic joint pain, not responding to conventional treatments.<sup>6</sup> Partial joint denervation addresses symptomatic pain avoiding the morbidity and the complications related to the use of more invasive procedure.<sup>7</sup>

In his series of publications, Dellon describes the anatomy of the sensitive innervation of the main joints of the body affected by chronic pain including the shoulder, elbow, wrist, knee, and ankle<sup>2,8</sup> paving the way to selective denervations to relieve chronic pain across the body.

Posttraumatic knee and ankle pain without musculoskeletal explanation or joint instability is not only due to pure joint pain, but often associated with somatic sensitive nerve lesions. The contribution of nerve compression from scarring, nerve lesions due to excessive stretching, or direct nerve injury during surgery or trauma should be routinely investigated as possible causes of refractory knee and ankle pain to improve the quality of life of patients not responding to more conventional approaches.<sup>9,10</sup>

In this study, we describe our experience and strategy with knee and ankle peripheral nerve microsurgery in patients suffering from posttraumatic chronic pain. This paper aims to establish peripheral nerve microsurgery as a critical step in the algorithm of treatment of knee and ankle chronic pain.

## Patients and Methods

A retrospective investigation was performed among patients treated at our Institution between 2015 and 2018. We included in the study patients who underwent nerve surgery for posttraumatic chronic pain in the knee and ankle (>6 months since the onset of the symptoms). Patients were followed up 1 year after surgery.

34 patients were included (14 with chronic knee pain and 20 with chronic pain in the ankle) in this study.

All included patients were referred by an orthopaedic surgeon, after all musculoskeletal causes of pain and joint instability were excluded. All patients had previous imaging performed (radiographies and computed tomography [CT] scans or magnetic resonance imaging [MRI]) and were sub-

jected to electroneuromyography (ENMG) to exclude more proximal nerve compressions and evaluate major nerve trunks (such as common peroneal nerve) lesions or compressions.

All patients presented with handicapping pain, this was measured in the knee by the Oxford knee score, which had to be less than 20 and in the ankle by the Foot and Ankle Disability Index, which had to show at least 70% impairment.<sup>11,12</sup>

Pain evaluation at rest and during activities was documented on a visual analog scale (VAS: 0–10) before and 12 months after the surgical procedures. Reduction of 50% in VAS score was considered clinically significant. Pain control was the main reason of performing peripheral nerve surgeries, and as such it represented the primary outcome.

Improvements in the functional scales was measured as less than 50% (no improvement), 50 to 90% improvement (50% improvement), and >90% improvement (>90% improvement).

Secondary outcomes included drug (analgesics, anti-inflammatories, pregabalin, etc.) usage (average number of pills per day) for mitigating pain before and after surgery.

All included patients were unable to work preoperatively and ability to work 1 year postsurgery was evaluated.

Exclusion criteria were history of mental illness, opioid use, and other chronic diseases potentially contributing to the pain syndrome such as polymyalgia and nonresolved insurance litigation issues.

Statistical analysis was performed by nonparametric *t*-tests, and a *p* < 0.05 was considered significant.

## Diagnosis

All patients underwent specific physical examination, cutaneous pain was distinguished from articular pain, and the suspected target nerves were identified. In the outpatient clinic, all patients underwent high-frequency ultrasound-guided block of the selected nerve/nerves using a nonechoic blunt needle with small volumes (1–2 cc) of lidocaine 1%/nerve. The selective nerve block was repeated at least twice. Patients were asked to move the joint, walk, bend, jump, walk up and down stairs, and perform all movements limited or not possible before because of pain. Only patients experiencing a reduction in pain of >50% according to the VAS in both sessions were considered eligible for surgery.

## Surgical Approaches

### Knee

This study was aimed to improve pain in the knee area; the following nerves were tested and treated when indicated as described in ►Table 1.

### Ankle

This study was aimed to improve pain in the ankle area; the following nerves were tested and treated when indicated as described in the ►Table 2.

## Postoperative Rehabilitation

Regardless the location (knee or ankle) of surgery and the number of nerves treated, all patients were encouraged to

**Table 1** Nerves treated around the knee

Nerve	Medial retinacular (from vastus medialis nerve)	Lateral retinacular (from sciatic nerve)	Infrapatellar branch saphenous	Peroneal nerve
Somatic sensitive/ sensitive joint	Sensitive joint	Somatic sensitive	Somatic sensitive	Somatic sensitive
Function	Upper medial joint capsule innervation	Upper lateral joint capsule innervation	Lower medial quadrant skin innervation (plus joint capsule branches)	Lower lateral quadrant skin innervation (plus joint branches)
Denervation/neuroma treatment/ decompression	Denervation	Neuroma treatment	Neuroma treatment/ decompression	

**Table 2** Nerves treated around the ankle

Nerve	Deep peroneal nerve	Sural nerve	Superficial peroneal nerve
Somatic sensitive/ sensitive joint	Sensitive joint	Somatic sensitive	Somatic sensitive
Function	Sinus tarsi innervation (joint)	Retromalleolar skin innervation plus joint capsule branches)	Pre malleolar skin innervation
Denervation/neuroma treatment/ decompression	Denervation	Neuroma treatment	Neuroma treatment/Decompression

immediate weight-bearing while walking when possible. Full recovery from surgery took between 2 and 3 weeks for all patients.

## Results

### Knee

Mean age in the group of patients suffering from chronic knee pain was 53 years old (range: 22–75 years) and 10 women and 4 men were included.

Mechanism of injury was total knee arthroplasty for eight patients, severe knee sprain for three patients, and arthroscopy for the remaining three patients. Average time lag from onset of pain to peripheral nerve surgery was 5.4 years.

Five patients had one nerve, five had two nerves, two had three nerves, and two had two nerves treated (►Fig. 1A). The lateral retinacular nerve was the most affected nerve, found responsible for pain in seven patients. The lateral retinacular nerve was identified via a 3-cm incision in the upper lateral quadrant of the knee (►Fig. 1C). The nerve was dissected and isolated before entering the joint capsule (►Fig. 1D). The terminal branches of the nerve were divided, and the proximal stump was buried deep in muscle tissue (vastus lateralis) without any tension during extension and flexion of the knee (►Fig. 1E). A similar approach was used for the medial retinacular nerve when indicated (not shown). Pathologic findings from the analysis of the lateral and medial retinac-

ular nerve showed signs of perineural scarring and neuroma in continuity.

The common peroneal nerve, saphenous nerve, and medial retinacular nerves were found to be responsible for chronic pain in six patients (►Fig. 1B). While the common peroneal nerve was decompressed in all six cases, neuromas were found in branches of the saphenous nerves and treated as such (as described below for the nerves in the ankle region).

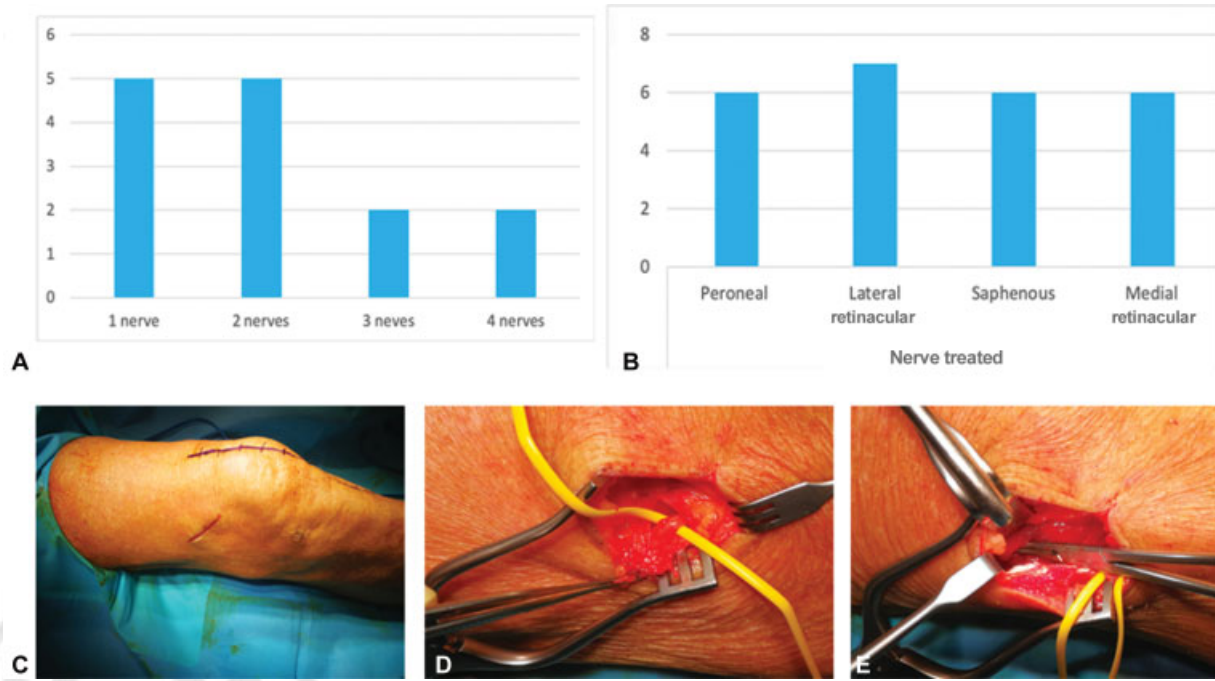
Pain evaluation at rest averaged 4.9/10 before surgery and 1.8/10 one year after surgery ( $p < 0.05$ ). Pain during activities decreased from 7.2/10 to an average of 3 ( $p < 0.01$ ; ►Fig. 2A).

Functional outcome from surgery was found nonsignificant in one patient, 50% improvement was found in eight patients and more than 90% improvement found in five patients (►Fig. 2B).

Daily drug usage averaged 2.6 pills before surgery and decreased to 0.5 pills 12 months after surgery ( $p < 0.01$ , ►Table 3).

All patients were unable to work before surgery, while ability to work averaged 71.4% after surgery ( $p < 0.01$ , ►Table 3).

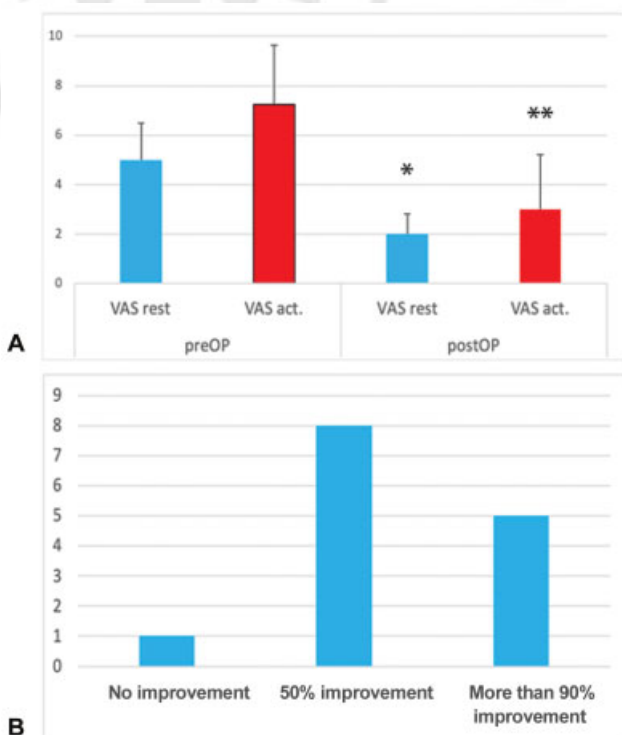
Of the 14 patients, 10 patients had only one surgical procedure, 3 patients had two surgeries (of which two were revision surgeries), and 1 patient had four surgeries (of which three were revision surgeries; not shown). Complications were found in five patients: one patient (after the



**Fig. 1** (A) Number of nerves treated. (B) Nerves surgically addressed to improve chronic knee pain. (C) The lateral retinacular nerve was found responsible for pain in seven patients. The nerve was found via a 3cm incision in the upper lateral quadrant of the knee. (D) The nerve was isolated before entering the joint capsule. (E) The terminal end of the nerve was divided and buried proximally, deep in muscle tissue, without any tension.

**Table 3** Average drug consumption (number of pills per day including analgesics, anti-inflammatories, and gabapentin) and ability to work (percentage) before and 12 months after surgery in patients included in the study for chronic knee pain

	Before surgery	Postsurgery	p-Value
Drug consumption (number of daily pills)	2.6	0.5	0.01
Ability to work (%)	0	71.4	0.01



**Fig. 2** (A) Average pain evaluation before (blue bars) and after peripheral nerve surgery in the knee surgery (red bars) at rest and during activities (\*pre vs. post <0.05, \*\*pre vs. post <0.01). (B) Outcome of surgery at 1 year follow-up. act., active; postOP, postoperative; preOP, preoperative; VAS, visual analogue scale.

fourth surgery) had a transient lymphoedema, two patients had neuroma recurrence, and need to be reoperated and two patients had transient neuropathy with hyperesthesia in the somatic territories of the nerves treated (with spontaneous resolution within 3 months).

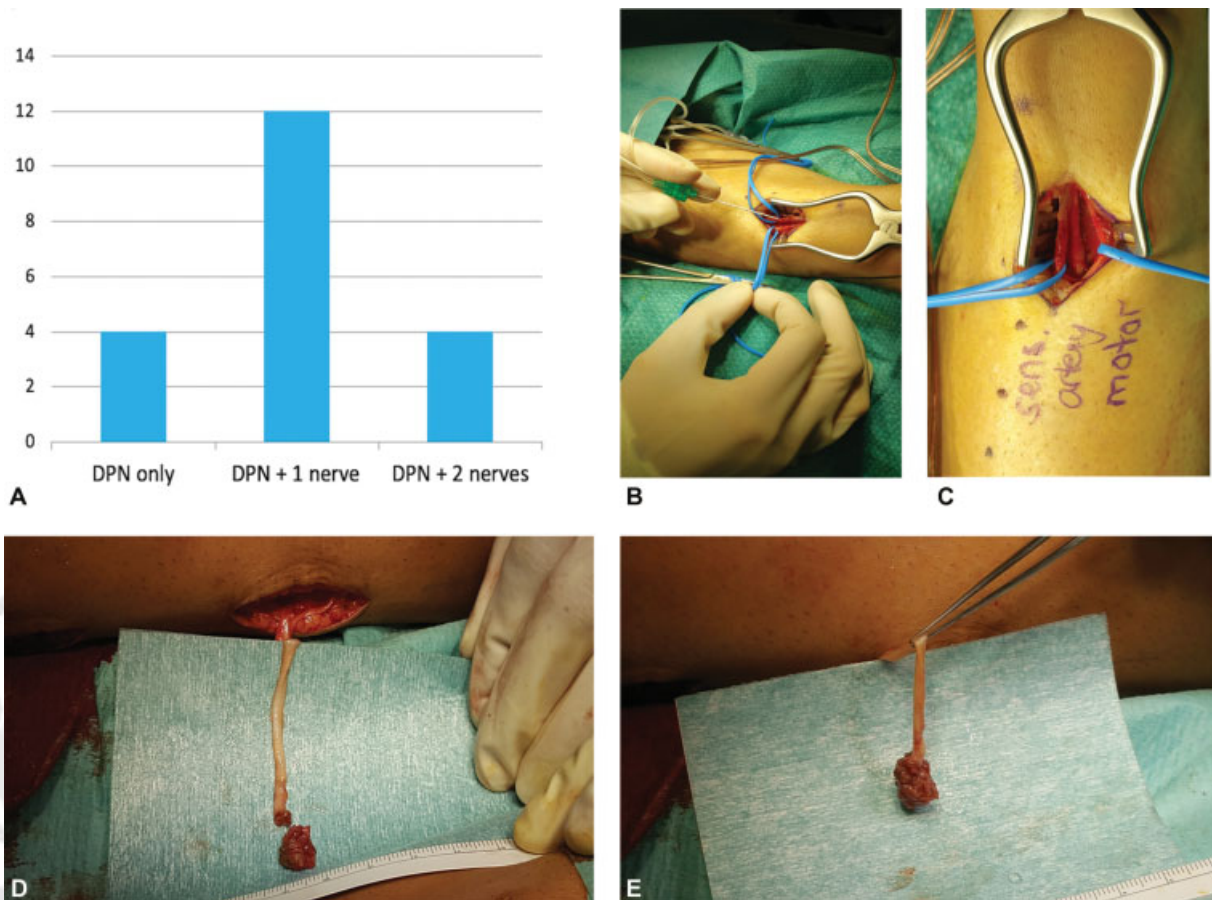
Neuroma recurrence occurred in two patients (once in one patient and thrice in another patient) and the saphenous nerve was involved in four cases. Surgical treatment to address recurrent neuromas was performed by excision of the injured segment and regenerative peripheral nerve interfaces (RPNI, discussed in the section that follows).

**Ankle**

Mean age in the group of patients suffering from ankle pain was 57 (range 23–70) years and 16 males and 4 females were included.

A total of 15 patients developed chronic pain after bone fractures (lateral malleolar, distal tibial, and calcaneal fractures), 5 patients had a severe inversion ankle sprain, and 5





**Fig. 3** (A) Nerve treated to improve chronic pain in the ankle. (B) Neurostimulation to identify the sensitive joint branches to the sinus tarsi of the deep peroneal nerve. (C) After intrafascicular microdissection the motor branches are separated from the sensitive nerve branches. Motor branches to the short extensor of the toes are spared and sensitive branches are divided. (D) When a neuroma was found and the distal end of the nerve was not identifiable, the lesioned part of the nerve was resected. (E) A free muscle graft was wrapped around the nerve stump with 8/0 nylon sutures. This technique is called regenerative peripheral nerve interfaces. DPN, deep peroneal nerve.

patients had subtalar arthrodesis after trauma. Average time lag from onset of pain to peripheral nerve surgery was 4.6 years.

In all patients, the deep peroneal nerve (DPN) was found responsible entirely or in part for the pain. In four patients the DPN was alone responsible for pain, in 12 patients the DPN was associated with another nerve (sural or superficial peroneal nerve) and in 4 patients, the DPN was found associated with two other nerves (sural and superficial peroneal nerve; ►Fig. 3A).

The DPN was found lesioned in 70% of the cases and the neuroma was surgically addressed as described below. In the remaining 30% of the cases, the DPN was intact and the sensitive distal part of the DPN to the sinus tarsi was isolated via intrafascicular dissection and intraoperative neurostimulation (►Fig. 3B) and divided sparing the motor fibers to the short extensor of the toes (►Fig. 3C). The nerve stump was buried deep into proximal muscle tissue in the absence of any tension.

The superficial peroneal nerve (SPN) was involved in 12 patients. In six cases, it was terminally damaged in one or multiple branches and neuromas were found. Neuromas were treated with RPNI when no distal end was identifiable. After neuroma resection, a free muscle graft was wrapped

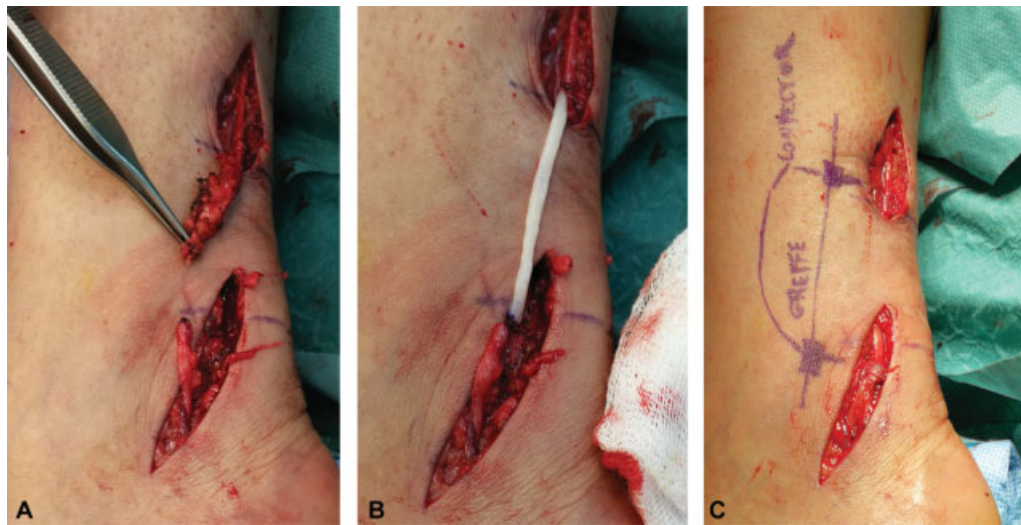
around the nerve stump with 8/0 nylon (Ethilon, J&J sutures, Livingstone, UK; ►Fig. 3D and E). In the other six cases, where the distal end of the nerve was identifiable, the nerve was reconstructed with an allograft.

The sural nerve was found injured in six cases and a neuroma was identifiable in all of them (►Fig. 4A). In three cases, the distal end was found and after resection of the injured segment, an allograft (Avance, Axogen Inc.) was used to bridge the gap (►Fig. 4B). The graft was sutured to the proximal and distal ends of the sural nerve with nylon 8/0. The connection sites were surrounded by a nerve protector (Axoguard, Axogen Inc.) to decrease the chances of axon escape and scar adhesions around the repair site (►Fig. 4C).

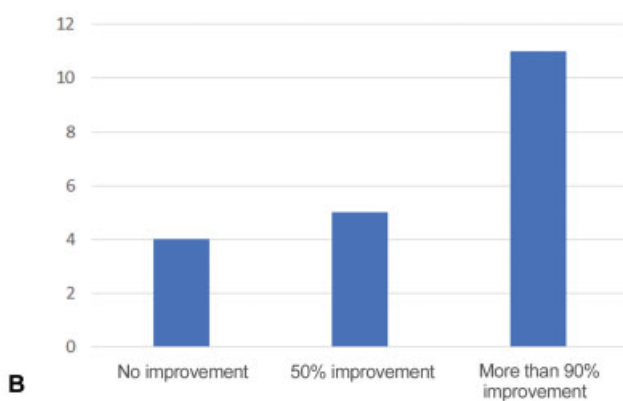
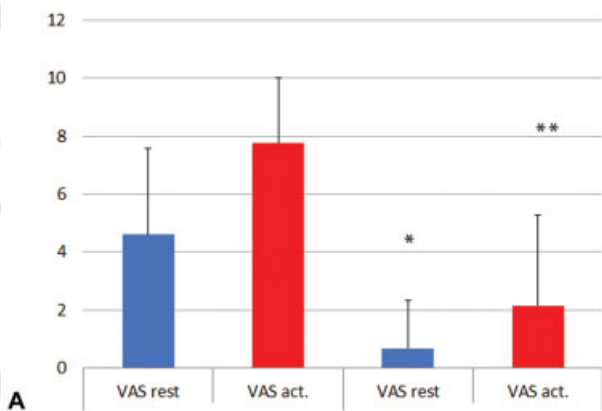
In the remaining three cases of sural nerve neuroma, an RPNI was utilized for neuroma treatment.

Average ankle pain at rest was 4.6/10 before surgery and 0.7/10 after surgery, showing a 3.9/10 average reduction ( $p < 0.05$ ). Pain during activities averaged 7.8 before surgery and reached 2.1, 12 months after surgery ( $p < 0.05$ ; ►Fig. 5A).

One year after surgery, four patients did not reach a significant functional improvement, while five patients reached 50% improvement and 11 patients returned to almost normal ankle function (►Fig. 5B).



**Fig. 4** (A) The sural was injured in 6 cases and a neuroma was found. (B) When the distal end of the nerve was found, after resection of the lesioned segment an allograft was used to bridge the gap. (C) The repair sites between the nerve and the graft were protected with a wrap to decrease the chances of complications (axonal escape from the repair site and scar adhesions).



**Fig. 5** (A) Average pain evaluation before (blue bars) and after peripheral nerve surgery in the ankle (red bars) at rest and during activities (\*pre vs. post <0.05, \*\*pre vs. post <0.01). (B) Outcome of surgery at 1 year follow-up. act., active; VAS, visual analogue scale.

Daily drug usage averaged 4.1 pills before surgery and decreased to 0.8 pills 12 months after surgery ( $p < 0.01$ , **Table 4**).

**Table 4** Average drug consumption (number of pills per day including analgesics, anti-inflammatories, and gabapentin) and ability to work (percentage) before and 12 months after surgery in patients included in the study for chronic ankle pain

	Before surgery	Postsurgery	p-Value
Drug consumption (number of daily pills)	4.1	0.8	0.01
Ability to work (%)	0	73.7	0.01

All patients were unable to work before surgery, while ability to work averaged 73.7% after surgery ( $p < 0.01$ , **Table 4**).

Complications were found in four patients, all requiring reoperation due to neuroma recurrence, three after neuroma resection (two in the superficial peroneal nerve and one in the sural nerve) and treatment by RPNI, and one after allograft treatment (for the reconstruction of the superficial peroneal nerve).

All these cases of recurrent neuroma were treated by section of the nerve proximal to the injured segment and RPNI.

### Discussion

This retrospective analysis illustrates that with a careful selection of the surgical candidates, peripheral nerve microsurgery can be of significant help to decrease chronic knee and ankle pain, in particular when musculoskeletal etiologies have been ruled out, and when all other measures have failed.

Results from peripheral nerve surgery in the knee show up to 92% success rates (patients with more than 50% improvement), with over 35% of patients having an almost complete remission of pain, ability to work, and independence from pain killer. In the ankle, overall success rate was

80% (with more than 50% improvement), with 55% of patients returning to an almost normal life. Interestingly, at 12-month follow-up, while 7% of the patients operated for chronic knee pain and 20% of the patients operated around the ankle did not show any significant improvement, no patients reported a deterioration of the situation.

When dealing with patients with chronic pain, the quantification of the results of a given intervention is quite difficult as several factors are involved and influence the overall results, including drug abuse, psychological distress, anxiety, and work compensation-related issues.<sup>13</sup> To evaluate the outcome from peripheral nerve surgeries in the knee and ankle, we analyzed several parameters, combining functional indexes, pain at rest, and during movement, drug use and ability to work. When combined, these results provide a clear, semiquantitative outcome of the surgery.

From the analysis of the results, we found that, saphenous and superficial peroneal nerve neuromas were the less reliable conditions to treat. Seven reoperations (four on the saphenous nerve and three on the superficial peroneal nerve) were performed to treat a recidivating neuroma. This might be due to multiple reasons: first of all, the presence of several branches networking in a restricted area making it almost impossible to obtain a precise diagnostic by ultrasound-guided nerve blocks; second, the possibility that multiple ones are involved at the same time but only one was treated; and finally, the mobility of these areas around joint makes that neuroma treatment unstable.<sup>14,15</sup> According to the most recent literature, targeted muscle reinnervation (TMR, i.e., the coaptation of the distal end of the affected nerve after neuroma resection to a nearby motor branch) may be associated to a reduced recurrence rate of neuromas.<sup>16</sup> This approach holds promise for the future, but not enough evidence is available at the moment to affirm the superiority of one approach to another to treat neuromas.

Patient were referred for peripheral nerve evaluation only 5.4 (knee) and 4.6 (ankle) years of suffering after the trauma. This delay makes full recovery, including physical psychological, professional, and social spheres very difficult. One of the reasons might be that SNMGs tests do not have the sensibility to test for small terminal articular branches and cannot measure pain fibers.<sup>17</sup> Consequently, for most patients, these tests result normal, so that family practitioners, neurologists, and orthopaedic surgeons might believe that there is no indication for peripheral nerve evaluation. As the awareness of these positive results expand and more academic centers around the world start to adopt these techniques, we believe that patients in the near future will not have to suffer so long anymore and will be referred for peripheral nerve evaluation as part of the standard treatment.

Given these results, with similar outcomes from the literature,<sup>9,10,18</sup> peripheral nerve microsurgery should be added in the algorithm of treatment of chronic knee and ankle pain (► Fig. 6). After 6 months, 1 year from the onset, when conservative options (such as splinting, physical therapy, occupational therapy, and drugs) and less invasive approaches (infiltrations from pain management specialists) have failed to provide a stable improvement, peripheral

**Chronic (6-12 months) Knee or Ankle pain  
without musculoskeletal disorders**

**Treatment algorithm**

**Conservative measures**

Splinting, physical therapy  
Occupational therapy, drugs



**Minimally invasive  
Pain management**

Local infiltrations



**Minimally invasive  
Peripheral nerve surgery**



**Joint arthroscopy**



**Joint fusion/Replacement**



**Neurostimulators**

**Fig. 6** Treatment algorithm.

nerve surgery should be considered.<sup>19</sup> Since most musculoskeletal issues can be visualized with imaging methods, we believe that peripheral nerve evaluation should come before exploratory arthroscopies, procedures that have a rather high rate of complications.<sup>20,21</sup> Ankle arthroscopy, which is considered a standard procedure for diagnosis, has an incidence of neurovascular complication related to portal placement reaching 20% of cases according to some authors.<sup>22</sup> The SPN is the most injured nerve in those cases (70%), followed by the DPN.<sup>23</sup> For the knee, the incidence of infrapatellar articular branch lesion while performing knee arthroscopy can be as high as 20% of cases while the saphenous nerve injury ranges from 10 to 40% of cases.<sup>24</sup>

Joint fusion or replacement should not be performed for the sole indication of pain and palliative options, such as neurostimulators, should be kept as last resource (► Fig. 6).<sup>25</sup>

## Conclusion

Injury or compression of a sensory nerve is an underreported source of disabling chronic pain in the knee and ankle. Interrupting, rewiring, and repairing sensory innervation around the joints to reduce pain and improve function and quality of life of patients is nowadays a valuable tool for plastic surgeons and microsurgeons worldwide.

### Conflict of Interest

None declared.



### Acknowledgments

The authors acknowledge Drs. Robert Hagan, Ziv Peled, Ian Valerio, Shai Rozen, and Ivica Ducic for useful discussions and teachings.

### References

- 1 Nakagawa R, Yamaguchi S, Kimura S, et al. Association of anxiety and depression with pain and quality of life in patients with chronic foot and ankle diseases. *Foot Ankle Int* 2017;38(11):1192–1198
- 2 Dellon AL. Partial joint denervation II: knee and ankle. *Plast Reconstr Surg* 2009;123(01):208–217
- 3 Wilhelm A. [Articular denervation and its anatomical foundation. A new therapeutic principle in hand surgery. On the treatment of the later stages of lunatomalacia and navicular pseudarthrosis]. *Hefte Unfallheilkd* 1966;86:1–109
- 4 Berger RA. Partial denervation of the wrist: a new approach. *Tech Hand Up Extrem Surg* 1998;2(01):25–35
- 5 Ekerot L, Holmberg J, Eiken O. Denervation of the wrist. *Scand J Plast Reconstr Surg* 1983;17(02):155–157
- 6 Dellon AL. Partial dorsal wrist denervation: resection of the distal posterior interosseous nerve. *J Hand Surg Am* 1985;10(04):527–533
- 7 Braga-Silva J, Román JA, Padoin AV. Wrist denervation for painful conditions of the wrist. *J Hand Surg Am* 2011;36(06):961–966
- 8 Dellon AL. Partial joint denervation I: wrist, shoulder, and elbow. *Plast Reconstr Surg* 2009;123(01):197–207
- 9 Dellon AL, Mont MA, Mullick T, Hungerford DS. Partial denervation for persistent neuroma pain around the knee. *Clin Orthop Relat Res* 1996;(329):216–222
- 10 Dellon AL, Barrett SL. Sinus tarsi denervation: clinical results. *J Am Podiatr Med Assoc* 2005;95(02):108–113
- 11 Petersen CL, Kjærsgaard JB, Kjærsgaard N, Jensen MU, Laursen MB. Thresholds for Oxford Knee Score after total knee replacement surgery: a novel approach to post-operative evaluation. *J Orthop Surg Res* 2017;12(01):89
- 12 Hale SA, Hertel J. Reliability and sensitivity of the foot and ankle disability index in subjects with chronic ankle instability. *J Athl Train* 2005;40(01):35–40
- 13 Jones AR, Al-Naseer S, Bodger O, James ETR, Davies AP. Does pre-operative anxiety and/or depression affect patient outcome after primary knee replacement arthroplasty? *Knee* 2018;25(06):1238–1246
- 14 Horner G, Dellon AL. Innervation of the human knee joint and implications for surgery. *Clin Orthop Relat Res* 1994;(301):221–226
- 15 Shi GG, Williams MA, Whalen JL, Wilke BK, C Kraus J. An anatomic and clinical study of the innervation of the dorsal midfoot capsule. *Foot Ankle Int* 2019;40(10):1209–1213
- 16 Poppler LH, Parikh RP, Bichanich MJ, et al. Surgical interventions for the treatment of painful neuroma: a comparative meta-analysis. *Pain* 2018;159(02):214–223
- 17 Garcia-Larrea L, Hagiwara K. Electrophysiology in diagnosis and management of neuropathic pain. *Rev Neurol (Paris)* 2019;175(1–2):26–37
- 18 Dellon AL, Mont MA, Krackow KA, Hungerford DS. Partial denervation for persistent neuroma pain after total knee arthroplasty. *Clin Orthop Relat Res* 1995;(316):145–150
- 19 Gohritz A, Dellon AL, Kalbermatten D, Fulco I, Tremp M, Schaefer DJ. Joint denervation and neuroma surgery as joint-preserving therapy for ankle pain. *Foot Ankle Clin* 2013;18(03):571–589
- 20 Friberger Pajalic K, Turkiewicz A, Englund M. Update on the risks of complications after knee arthroscopy. *BMC Musculoskelet Disord* 2018;19(01):179
- 21 Barber FA, Click J, Britt BT. Complications of ankle arthroscopy. *Foot Ankle* 1990;10(05):263–266
- 22 Zengerink M, van Dijk CN. Complications in ankle arthroscopy. *Knee Surg Sports Traumatol Arthrosc* 2012;20(08):1420–1431
- 23 Yammine K, Assi C. Neurovascular and tendon injuries due to ankle arthroscopy portals: a meta-analysis of interventional cadaveric studies. *Surg Radiol Anat* 2018;40(05):489–497
- 24 Mochida H, Kikuchi S. Injury to infrapatellar branch of saphenous nerve in arthroscopic knee surgery. *Clin Orthop Relat Res* 1995;(320):88–94
- 25 Beswick AD, Wylde V, Goberman-Hill R, Blom A, Dieppe P. What proportion of patients report long-term pain after total hip or knee replacement for osteoarthritis? A systematic review of prospective studies in unselected patients. *BMJ Open* 2012;2(01):e000435